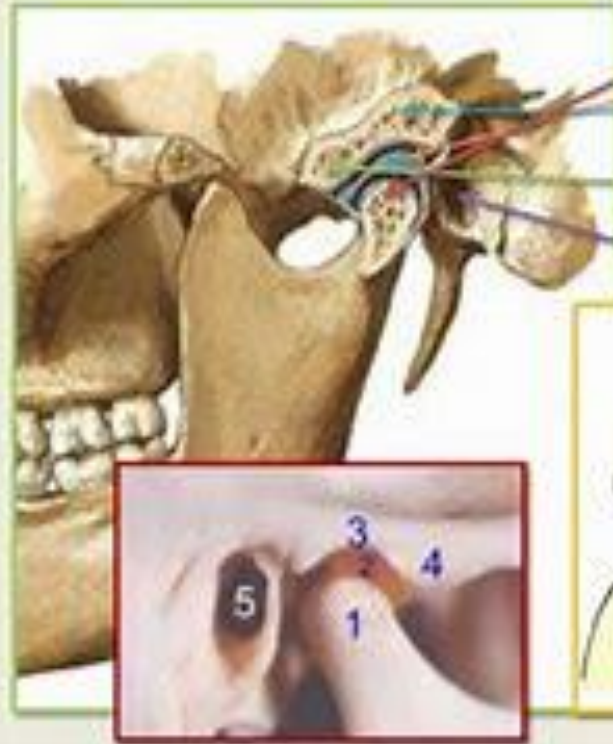
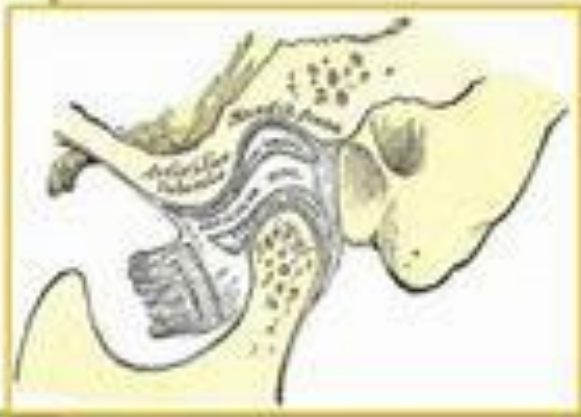

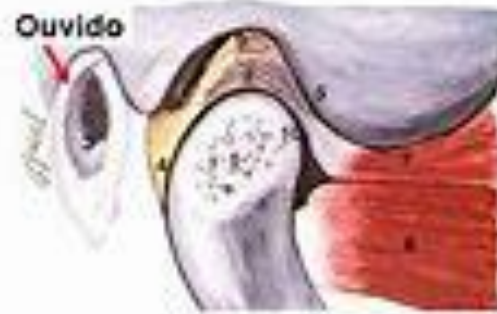ESTRUCTURA DE LA ATM



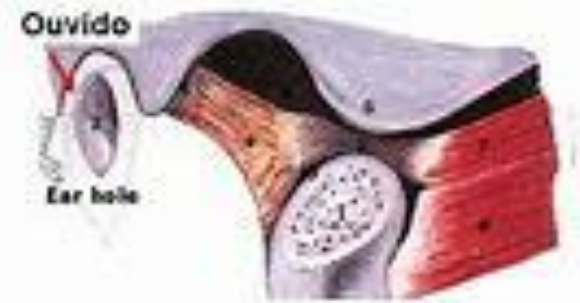1. Cóndilo mandibular.
2. Menisco o disco articular.
3. Cavidad glenoidea del temporal.
4. Eminencia o tubérculo del temporal.
5. Conducto auditivo externo

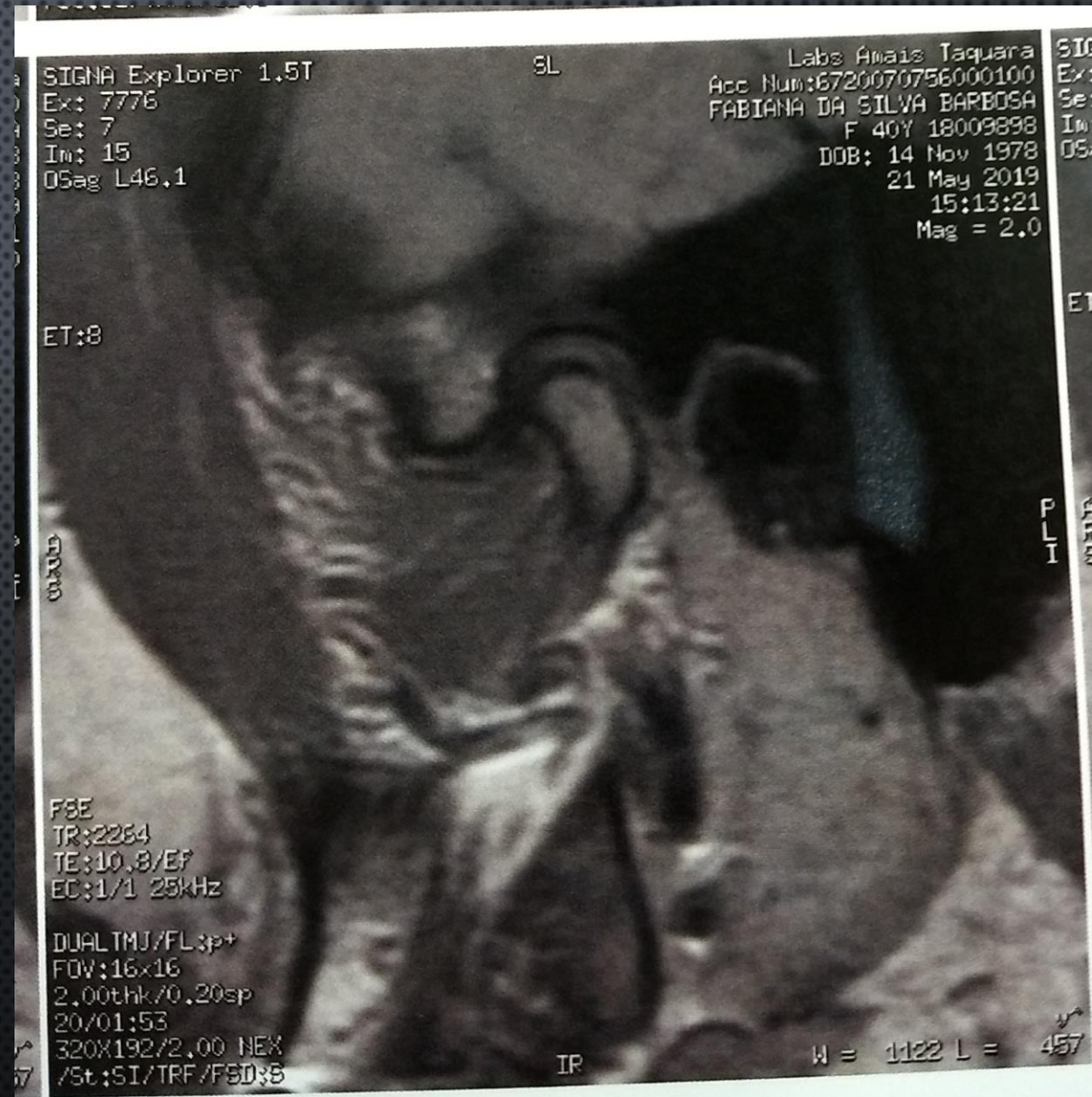
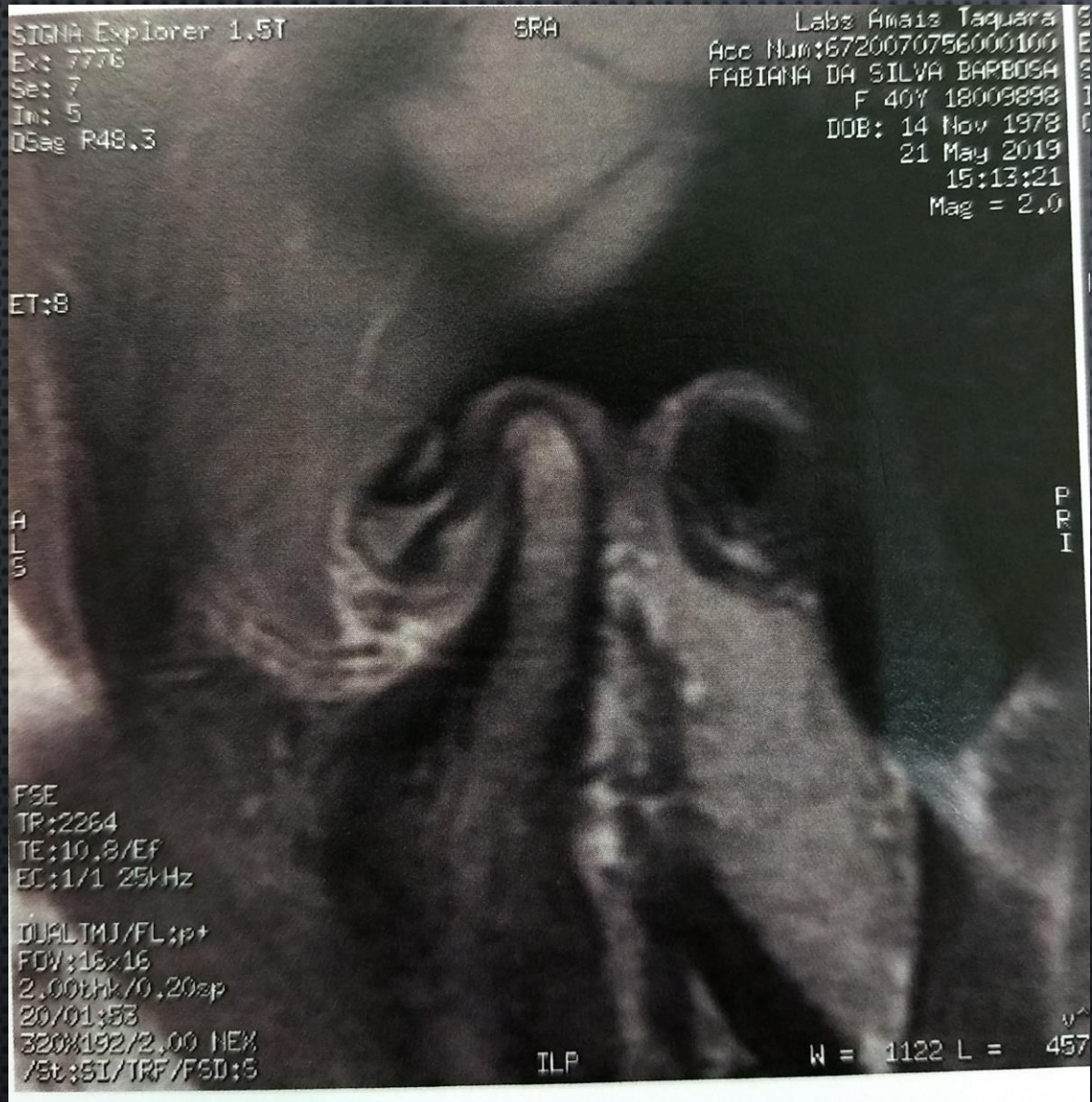
Boca fechada



Boca abierta





SIGNA Explorer 1.5T
Ex: 7776
Se: 9
In: 6
DSeg R46.2

SKH

Acc Num:6720070756000100
FABIANA DA SILVA BARBOSA
F 40Y 18009898
DOB: 14 Nov 1978
21 May 2019
15:19:45
Mag = 2.1

Ex:
Se:
In:
DS

ET:8

ET

P
L
I

P
L
I

FSE
TR:2264
TE:10.8/EF
EC:1/1 25kHz

DUALTMJ
FOV:16x16
2.00thk/0.20sp
20/01:53
320X192/2.00 NEX
/St:SI/TRF/FSD:5

ILP

W = 3916 L = 1715

SIGNA Explorer 1.5T
Ex: 7776
Se: 9
In: 15
DSeg L46.1

SL

Labs Amais Taquara
Acc Num:6720070756000100
FABIANA DA SILVA BARBOSA
F 40Y 18009898
DOB: 14 Nov 1978
21 May 2019
15:19:45
Mag = 2.1

Ex:
Se:
In:
DS
DSeg

ET:8

P
L
I

P
L
I

FSE
TR:2264
TE:10.8/EF
EC:1/1 25kHz

DUALTMJ
FOV:16x16
2.00thk/0.20sp
20/01:53
320X192/2.00 NEX
/St:SI/TRF/FSD:5

IR

W = 3916 L = 1715